

# Recurrent and Persistent Coagulopathy Following Pit Viper Envenomation

Leslie V. Boyer, MD; Steven A. Seifert, MD; Richard F. Clark, MD; Jude T. McNally, RPh; Saralyn R. Williams, MD; Sean P. Nordt, PharmD; Frank G. Walter, MD; Richard C. Dart, MD, PhD

**Background:** Coagulation abnormalities following crotaline (pit viper) snakebite have traditionally been considered short-lived, but laboratory studies have rarely been reported beyond the first few days of treatment for envenomation. During the course of an antivenom clinical trial, we observed coagulation defects as late as 2 weeks following envenomation.

**Objectives:** To document and characterize the recurrence or persistence of coagulopathy among patients envenomed by pit vipers and treated with a Fab antivenom.

**Methods:** Patients with moderate pit viper envenomation were enrolled in a multicenter, prospective clinical trial. A Fab-based antivenom preparation, antivenom polyvalent crotalid (ovine) Fab, was administered in all cases. Platelet count, fibrinogen level, presence of fibrin split products, prothrombin time, and partial thromboplastin time were determined before treatment and at standard intervals during the following 2 weeks.

**Results:** Of 38 patients completing the study, 20 (53%) had recurrent, persistent, or late coagulopathy 2 to 14 days after envenomation. Thrombocytopenia occurred in patients with prior thrombocytopenia; hypofibrinogenemia occurred only in those with prior hypofibrinogenemia or positive fibrin split products. No patient experienced significant spontaneous bleeding. One patient with coagulopathy developed minor bleeding following minor surgery 12 days after envenomation.

**Conclusions:** Prolonged or recurrent coagulopathy may occur after envenomation by North American pit vipers. Patients treated with Fab-based antivenom may benefit from periodic rather than single-bolus dosing. Patients with coagulopathy should undergo close monitoring during the first 2 weeks after snakebite.

*Arch Intern Med.* 1999;159:706-710

From the Departments of Pediatrics (Dr Boyer) and Surgery (Dr Walter) and College of Pharmacy (Mr McNally), University of Arizona Health Sciences Center and Arizona Poison and Drug Information Center (Dr Boyer and Mr McNally) and Department of Emergency Medicine, Kino Community Hospital (Dr Seifert), Tucson, Ariz; Department of Emergency Medicine and California Poison Control System, San Diego Division (Drs Clark, Williams, and Nordt), and Department of Emergency Medicine, University of California at San Diego (Drs Williams and Nordt); and Rocky Mountain Poison and Drug Center, Denver Health Department, and Colorado Emergency Medicine Research Center, University of Colorado, Denver (Dr Dart).

**N**ORTH AMERICAN snakes of the Crotalinae subfamily (pit vipers) include rattlesnakes (*Crotalus* species), pygmy rattlesnakes and massasaugas (*Sistrurus* species), and moccasins (*Agkistrodon* species). The coagulation defects observed in patients treated for pit viper envenomation have traditionally been considered short-lived. Long-term coagulation monitoring is rarely described in the literature, and very few reports of late coagulopathy have been published. It is common practice to discharge patients from the hospital, once coagulation abnormalities have apparently resolved, without expectation of follow-up blood evaluation.

For many years, the mainstay of pit viper envenomation treatment in the United States has been a horse serum-based, whole antibody preparation, Antivenin (Crotalidae) Polyvalent (ACP; Wyeth, Marietta, Penn). Recently, use of

Fab-based preparations has been reported as an alternative to whole IgG immunotherapy for snakebite<sup>1</sup> and in treatment of digoxin overdose,<sup>2</sup> largely in an effort to minimize the risk of immediate hypersensitivity and delayed serum sickness.<sup>3</sup> Consroe et al<sup>4</sup> have reported the efficacy of such a product, antivenom polyvalent crotalid (ovine) Fab (CroTAB; Therapeutic Antibodies, Inc, Nashville, Tenn) (FabAV), to prevent crotalin venom-induced lethality in mice with a potency 4 to 5 times greater than that of ACP.<sup>4</sup> Dart et al<sup>5</sup> have reported the first use of this agent in the treatment of humans with pit viper envenomation.<sup>5</sup> In the present study, blood coagulation parameters were monitored beyond the usual in-hospital observation period. We observed late coagulation abnormalities in some patients. Our purpose was to document and characterize the persistence or recurrence of venom effect in these patients, during the 2 weeks following envenomation.

## PATIENTS AND METHODS

The first multicenter, prospective clinical trial of FabAV in 11 patients has been presented by Dart et al.<sup>3</sup> For our study, institutional review board approval was granted at all participating institutions. Inclusion criteria included age older than 10 years and presentation with progressive symptoms within 6 hours of mild or moderate envenomation by a North American pit viper. Exclusion criteria included bite by the copperhead snake (*Agkistrodon contortrix*); prior infusion of more than 1 vial of ACP; presence of major organ disease that, in the investigator's judgment, would interfere with evaluation of the patient; history of hypersensitivity to any sheep-derived product; pregnancy or lactation; and use of systemic corticosteroids, experimental drugs, or other contraindicated medication in the judgment of the investigator. Informed consent was obtained from all patients after the nature of the study had been explained. All patients received an initial stabilizing dose of 4 to 8 vials of antivenom. Total antivenom dose was determined by individual investigators, on the basis of progressive local change or ongoing coagulopathy.

Following the first patient series, 31 subsequent patients were enrolled in a companion trial, with randomization between 2 dosing schedules. Patients in the second trial were subject to the same inclusion and exclusion criteria, and all provided informed consent. They initially received 6 to 12 vials of antivenom, then were randomized to receive subsequent doses on either an as-needed or

a scheduled basis. Patients in the scheduled group received three 2-vial doses, 6 hours apart. Patients remained hospitalized for 36 to 48 hours and returned for follow-up evaluations through 14 days after discharge.

For this analysis, records of all patients receiving the study drug and completing at least 4 days of either trial were reviewed. Because timing of administration and overall antivenom dose varied among individual patients, study groups were combined for analysis, rather than compared. Abnormalities in prothrombin time (PT), partial thromboplastin time (PTT), platelet count, fibrinogen level, and presence of fibrin split products (FSPs) were noted whenever values were outside the reference ranges defined by the participating hospital laboratories. The term "coagulopathy" was applied in cases of thrombocytopenia, prolonged PT or PTT, or hypofibrinogenemia.

Based on a usual hospital-phase treatment course of 48 hours' duration, coagulation abnormalities were defined as stabilized, persistent, recurrent, or late. Coagulopathy patterns were defined as follows: "stabilized," the abnormality corrected within 48 hours and did not recur; "persistent," the value did not return to normal by the time of discharge; "recurrent," the value was abnormal within the first 12 hours, became normal, and then returned to abnormal; and "late," abnormality occurred de novo 12 hours or more following the first antivenom administration.

Variability among patient subsets with and without specific coagulation abnormalities was compared using 2-tailed Fisher exact tests, with sensitivities, specificities, and predictive values calculated from standard definitions.

## RESULTS

Of 42 patients enrolled, 4 withdrew within 4 days of study involvement, leaving 38 with evaluable late coagulation data. Consistent with the study design, all patients demonstrated progressive local injury at the time of enrollment. All patients received initial stabilizing doses of the study antivenom (range, 4-12 vials); 28 received subsequent doses. The average total dose was 10.9 vials (range, 4-18 vials). Local manifestations in all patients stabilized by 24 hours after study enrollment, and none of the patients showed extension of local injury during follow-up.

Of the 38 patients analyzed, 29 (76%) developed coagulopathy at some point during their course (**Table**). Twenty-eight (74%) had at least 1 element of coagulopathy before or within 1 hour of the first antivenom administration. Twenty patients (53%) had multicomponent coagulopathy (eg, hypofibrinogenemia and thrombocytopenia). In all, 14 patients (37%) developed thrombocytopenia, 22 (58%) developed hypofibrinogenemia, and 17 (45%) developed prolonged PT or PTT. Extremely prolonged PT or PTT (greater than twice normal) occurred in 4 patients (11%), all of whom had simultaneous severe hypofibrinogenemia (below detection limit for the participating laboratory). Thirty-two patients (84%) exhibited positive FSPs at some time during their course; 6 patients developed positive FSPs as their only laboratory abnormality during the first 48 hours and were not

scored as having coagulopathy at that time. Three patients (8%) had normal coagulation studies throughout their courses.

Among the 29 patients with coagulopathy were 20 with late, persistent, or recurrent thrombocytopenia or hypofibrinogenemia. Among these patients were 12 with thrombocytopenia, 8 with prolonged PT or PTT, and 19 with hypofibrinogenemia. Thrombocytopenia was noted at follow-up only in patients with prior thrombocytopenia. Hypofibrinogenemia and PT or PTT prolongation were noted at follow-up only in patients with early hypofibrinogenemia or prior FSP elevation.

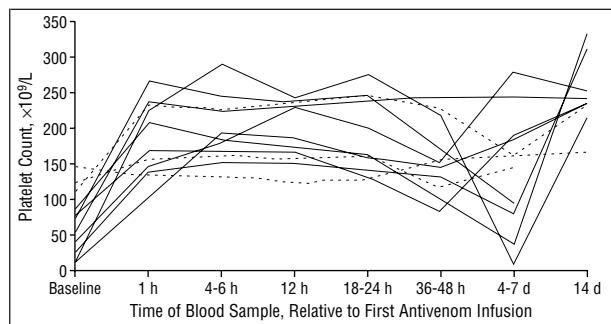
Among the 20 patients with late, persistent, or recurrent coagulopathy, 16 were observed without further treatment. Twelve of these cases resolved spontaneously within 2 weeks, and 4 patients had ongoing hypofibrinogenemia (2 with elevated PT) 14 days after enrollment. One patient with recurrent coagulopathy withdrew from the study at 1 week, and 1 was lost to follow-up after 4 days. Two received supplemental doses of FabAV during follow-up and had normal laboratory findings 2 weeks after the bite.

All patients with hypofibrinogenemia on presentation showed an increase in fibrinogen levels between hours 1 and 12 after the first antivenom dose, suggesting response to treatment. Hypofibrinogenemia within the first 12 hours of treatment predicted subsequent hypofibrinogenemia with 67% sensitivity, 70% specificity, 59% positive predictive value, and 76% negative predictive

**Number of Patients With Specific Coagulation Abnormalities in Normal, Stabilized, Recurrent, Late, and Persistent Patterns (N = 38)\***

Pattern	No. (%) of Patients				
	Platelet Count	Fibrinogen Level	Prothrombin Time	Partial Thromboplastin Time	Any Abnormality
Normal	24 (63)	16 (42)	21 (55)	28 (74)	Not applicable
Stabilized	5 (13)	7 (18)	10 (26)	5 (13)	16 (42)
Recurrent	7 (18)	7 (18)	5 (13)	2 (5)	14 (37)
Late	2 (5)	5 (13)	2 (5)	3 (8)	9 (24)
Persistent	0	3 (8)	0	0	3 (8)
Any abnormality	14 (37)	22 (58)	17 (45)	10 (26)	29 (76)

\*Coagulopathy pattern definitions were based on platelet counts, fibrinogen levels, prothrombin times, or partial thromboplastin times outside the reference ranges of participating hospital laboratories. "Stabilized" abnormalities corrected within 48 hours and never recurred; "recurrent" abnormalities were recognized within the first 12 hours, became normal, and then returned to abnormal at a later time; "late" abnormalities occurred de novo 12 hours or more following first antivenom administration; and "persistent" abnormalities did not return to normal by the time of hospital discharge.



Platelet count vs time course for patients presenting with thrombocytopenia. In general, platelet counts of patients with thrombocytopenia normalized 1 hour after antivenom polyvalent crotalid (ovine) Fab infusion, but many exhibited recurrent thrombocytopenia 4 to 7 days after treatment. This effect was more pronounced in patients with initial platelet counts less than  $100 \times 10^9/L$  (solid lines) than in those with counts between  $100 \times 10^9/L$  and  $150 \times 10^9/L$  (dashed lines).

value ( $P < .05$ ). Presence of FSPs within the first 12 hours of treatment predicted subsequent hypofibrinogenemia with 87% sensitivity, 69% specificity, 65% positive predictive value, and 89% negative predictive value ( $P < .05$ ).

One hypofibrinogenemic patient developed complications of bleeding during his course of treatment. This occurred 12 days after the bite, when he underwent incision and drainage of external hemorrhoids. Fibrinogen was undetectable. Hematocrit, which had been 0.36 on the second day following the bite, reached a low of 0.30. Local bleeding was controlled with pressure, no blood products were administered, and findings of coagulation studies began to normalize within the next 24 hours.

Of the 8 patients with initial platelet counts less than  $100 \times 10^9/L$ , all showed a rise in platelet count over the first 12 hours, with recurrent thrombocytopenia between 36 hours and 7 days after the bite (Figure, solid lines). Three patients presenting with mild thrombocytopenia (platelet count  $100 \times 10^9/L$  to  $150 \times 10^9/L$ ), remained relatively stable over time (Figure, dashed lines). Two patients developed late, mild thrombocytopenia, at 12 and 48 hours. Thrombocytopenia of platelet count less than  $150 \times 10^9/L$  within the first 12 hours of treatment predicted subsequent thrombocytopenia with 78% sensitivity, 83% specificity, 58% positive predictive value,

and 93% negative predictive value ( $P < .01$ ). Severe thrombocytopenia (platelet count  $< 100 \times 10^9/L$ ) within the first 12 hours of treatment predicted subsequent severe thrombocytopenia with 100% sensitivity, 97% specificity, 88% positive predictive value, and 100% negative predictive value ( $P < .01$ ).

**COMMENT**

Our observations suggest that significant hypofibrinogenemia and thrombocytopenia, lasting up to 2 weeks, may be common after envenomation by North American pit vipers. Rates of recurrence and persistence of coagulopathy this long after pit viper envenomation have not been addressed previously in the medical literature; to our knowledge, this is the only case series in which such an analysis has been done.

The clinical significance of late pit viper-associated coagulopathy is uncertain. None of our patients had spontaneous, clinically significant bleeding, consistent with most previous experience. In crotalin snakebite, hypofibrinogenemia alone is generally not associated with bleeding,<sup>6-8</sup> although complex coagulopathy in the first days following crotalid snakebite has been associated with life-threatening bleeding disorders.<sup>9</sup> The case in this series, in which bleeding followed hemorrhoid surgery in the presence of an unmeasurable fibrinogen level, is consistent with reports that patients with hypofibrinogenemia of other causes are at increased risk of hemorrhagic complications from surgery or significant trauma.<sup>10</sup> In the absence of definitive data, low fibrinogen levels, prolonged PTs, and low platelet counts should be considered potentially clinically significant, and persistence or recurrence of these coagulopathies should be managed with close follow-up and perhaps additional antivenom.

The fact that 20 (53%) of the 38 patients in our series had late, persistent, or recurrent coagulopathy suggests that clinical predictors should be developed to identify patients at risk of bleeding during the outpatient follow-up. Our data indicate that like predicts like: the best indicator of late thrombocytopenia is early thrombocytopenia, and the degree of recurrent thrombocytopenia may correlate with that noted on presentation. Similarly, the most promising predictor of late eufibrino-

genemia is early absence of FSPs; the most specific predictor of late hypofibrinogenemia is early hypofibrinogenemia. In theory, a patient treated very promptly after envenomation might have entirely normal initial laboratory findings despite the potential for late coagulopathy, but in this series there was no such case. In other words, a patient with a normal platelet count and absence of FSPs during the hospital phase of care is likely not to show coagulopathy at follow-up. A patient with a low platelet count or fibrinogen level on presentation should be monitored closely for recurrence; and additional antivenom dosing may be needed.

**I**t is noteworthy that the time course for improvement of local injury was much shorter in our patients than that for resolution of coagulopathy. Despite the appearance of late and recurrent coagulopathy in many patients, all had much-improved local manifestations at follow-up. This discordance in course may indicate differences in clearance of the various venom components from the bite site and the body.

Although no comparable study or case series has documented postdischarge coagulation studies in ACP-treated patients, our observation that coagulopathy may persist or recur following rattlesnake envenomation is consistent with past reports. Bogdan and Dart<sup>11</sup> reviewed 354 sequential envenomations reported to a regional poison center, of which 112 involved ACP-treated patients with coagulopathy. Of these, 13 (11.6%) showed recurrence during hospitalization. Hardy et al<sup>12</sup> reported recurrent thrombocytopenia after transient normalization in a patient bitten by a *Crotalus molossus* and treated with ACP. Other authors<sup>13-15</sup> described thrombocytopenia persisting for 7 to 14 days following envenomation by *Crotalus horridus horridus*; Lyons<sup>16</sup> reported a case of a *Crotalus ruber ruber* bite treated with 13 vials of antivenom, with ongoing thrombocytopenia 8 days after the bite. Budzynski et al<sup>17</sup> described a patient with a *Crotalus atrox* bite treated without antivenom, with persistently abnormal PT, thrombin time, and reptilase time 8 days after the bite. La Grange and Russell<sup>18</sup> described a similarly long course of thrombocytopenia in patients with envenomations by *Crotalus viridis helleri*.

Treatment with FabAV appears to have been effective at reversing the presenting coagulation abnormalities observed in our patients. All patients with significant coagulopathy showed improvement that persisted until at least 12 hours after the initial dose of antivenom, consistent with reported pharmacokinetics of other ovine Fab antivenoms.<sup>19</sup>

Few studies have elucidated the relationship between serum venom and antivenom levels in snakebite. Recurrent coagulopathy, involving both thrombocytopenia and hypofibrinogenemia, has been described in *Echis* envenomation and linked temporally to the fall of antivenom levels in the blood.<sup>20</sup> Meyer and colleagues<sup>21</sup> have compared the serum venom and antivenom levels of patients bitten by *Echis ocellatus* and treated with Fab or F(ab')<sub>2</sub> antivenoms. They demonstrated that a more rapid elimination of the Fab product was associated with re-

turn of venom antigenemia,<sup>21</sup> similar to that demonstrated in our *Crotalus*-envenomed patients. Ho and colleagues<sup>22</sup> showed an inverse relationship in the rise and fall of venom and antivenom (horse IgG) titers in a bite by the Malayan pit viper (*Calloselasma rhodostoma*). Ownby and colleagues<sup>23</sup> described a case of envenomation by *C. atrox* in which venom antigen was detectable in urine at 4 to 6 days, and ACP was detectable up to 4 months after presentation. Theakston et al<sup>24</sup> reported recurrent venom antigenemia in patients who received Haffkine polyspecific antivenom after envenomation by *Bungarus caeruleus* or *Naja naja naja*.

The recurrence of coagulopathy after apparent recovery in patients treated with Fab preparations such as FabAV probably results from the same mechanism responsible for the persistence of coagulopathy in patients treated with whole IgG preparations. In envenomed patients, ACP is reported to have a half-life of 61 to 194 hours<sup>20,25</sup>; FabAV is believed to have an effective half-life of less than 12 hours, and may require repeated doses to maintain effective circulating levels.<sup>26</sup> Rapid clearance of Fab antivenom may help explain the recurrence of hypofibrinogenemia and thrombocytopenia in our patients, assuming that unneutralized venom components themselves persist for many days after envenomation. Unfortunately, there is a paucity of published data on coagulation analyses 1 to 2 weeks following treatment of rattlesnake envenomation with ACP, rendering a complete comparison impossible; further studies are needed to clarify this point.

One possible mechanism to explain recurrent coagulopathy is a depot of unneutralized venom at the bite site. While circulating levels of Fab fall, unneutralized venom may continue to be released into the circulation, resulting in recurrent coagulopathy. Eventual exhaustion of the depot may then be followed by spontaneous resolution or by further neutralization of circulating venom by additional doses of antivenom. Studies demonstrating recurrence occurring in relation to the fall of protective antivenom levels support the theory of a depot of unneutralized venom.<sup>21,22</sup> In untreated bites, venom at the bite site should remain active until physiologically cleared or deactivated. In patients treated with antivenom, of either whole IgG or Fab origin, edema and circulatory injury at the bite site may limit delivery of antivenom to the venom depot, preventing or delaying neutralization.

A second mechanism for recurrent coagulopathy may be reversible binding of antivenom to venom proteins, with dissociation resulting in the reappearance of free circulating venom components. Recrudescence of antigen effect, presumably on the basis of dissociation of the Fab:antigen complex, has been reported in a patient with chronic renal failure treated with digoxin-specific Fab.<sup>27</sup> If this is the case with FabAV, then dissociation of Fab:venom complexes too large for rapid clearance may contribute to late coagulopathy. The molecular weight of Fab fragments, at about 50 kd,<sup>28</sup> is near the limit for renal excretion of neutral proteins.<sup>29</sup> Fab fragment complexation with venom components of molecular weights more than 20 kd<sup>30,31</sup> may thus result in Fab:venom complexes with significantly longer clearance times, giving the immune complexes time to dissociate.

In summary, hypofibrinogenemia, prolonged PT and PTT, and thrombocytopenia may be present in patients with pit viper bite up to 2 weeks following envenomation. The new Fab-based antivenom effectively reverses coagulopathy for the duration of its expected presence in the blood. The pattern of recurrent coagulopathy observed in our patients is consistent with ongoing release from a venom depot at the site of envenomation, or with dissociation of the circulating Fab:venom complex. Local reaction does not appear to worsen after the first 24 hours following stabilization with FabAV. Envenomed patients with significant coagulopathy should undergo close monitoring during the first 2 weeks following the bite.

Accepted for publication August 23, 1998.

This research was supported in part by funds from Therapeutic Antibodies, Incorporated, Nashville, Tenn, and by Orphan Product Development grant FD-R-000945-01-1 from the US Food and Drug Administration, Washington, DC.

Presented as a poster at the North American Congress of Clinical Toxicology, Portland, Ore, October 13, 1996.

Reprints: Leslie V. Boyer, MD, Arizona Poison and Drug Information Center, Health Sciences Center, Room 1156, 1501 N Campbell Ave, Tucson, AZ 85724.

## REFERENCES

1. Karlson-Stiber C, Persson H. Antivenom treatment in *Vipera berus* envenoming: report of 30 cases. *J Int Med*. 1994;235:57-61.
2. Woolf AD, Wenger TL, Smith TW, Lovejoy FH. Results of multicenter studies of digoxin-specific antibody fragments in managing digitalis intoxication in the pediatric population. *Am J Emerg Med*. 1991;9 (suppl 1):16-20.
3. Kirkpatrick CH. The Digibind Study advisory panel: allergic histories and reactions of patients treated with digoxin immune Fab (ovine) antibody. *Am J Emerg Med*. 1991;9(suppl 1):7-10.
4. Consroe P, Egen NB, Russell FE, et al. Comparison of a new ovine antigen binding fragment (Fab) antivenin for United States Crotalidae with the commercial antivenin for protection against venom-induced lethality in mice. *Am J Trop Med Hyg*. 1995;53:507-510.
5. Dart RC, Seifert SA, Carroll L, et al. Affinity-purified, mixed monospecific crotalid antivenom ovine Fab for the treatment of crotalid venom poisoning. *Ann Emerg Med*. 1997;30:33-39.
6. Van Mierop LHS. Poisonous snakebite: a review, 1: snakes and their venom. *J Fla Med Assoc*. 1976;63:191-199.
7. Reid HA. Defibrination by *Agkistrodon rodostoma* venom. In: Russell FE, ed. *Animal Toxins*. New York, NY: Pergamon Press; 1967:323-335.
8. Kitchens CS, Van Mierop LHS. Mechanism of defibrination in humans after envenomation by the Eastern diamondback rattlesnake. *Am J Hematol*. 1983;14:345-353.
9. Curry SC, Kunkel DB. Death from a rattlesnake bite. *Am J Emerg Med*. 1985;3:227-235.
10. Mammen EF. Fibrinogen abnormalities. *Semin Thromb Hemost*. 1983;9:1-9.
11. Bogdan GM, Dart RC. Recurrent coagulopathy following North American pit viper envenomation [abstract]. *J Toxicol Clin Toxicol*. 1996;34:592.
12. Hardy DL, Jeter M, Corrigan JJ. Envenomation by the Northern blacktail rattlesnake (*Crotalus molossus molossus*): report of two cases and the in vitro effects of the venom on fibrinolysis and platelet aggregation. *Toxicol*. 1982;20:487-493.
13. Hasiba U, Rosenbach LM, Rockwell D, Lewis JH. DIC-like syndrome after envenomation by the snake, *Crotalus horridus horridus*. *N Engl J Med*. 1975;292:505-507.
14. Furlow TG, Brennan LV. Purpura following timber rattlesnake (*Crotalus horridus horridus*) envenomation. *Cutis*. 1985;35:234-236.
15. Tallon RW, Koch KL, Barnes SG, Ballard JO. Envenomation coagulopathy from snakebites [letter]. *N Engl J Med*. 1981;305:1347.
16. Lyons WJ. Profound thrombocytopenia associated with *Crotalus ruber ruber* envenomation: a clinical case. *Toxicol*. 1971;9:237-240.
17. Budzynski AZ, Pandya BV, Rubin RN, et al. Fibrinogenolytic afibrinogenemia after envenomation by Western diamondback rattlesnake (*Crotalus atrox*). *Blood*. 1984;63:1-14.
18. La Grange E, Russell FE. Blood platelet studies in man and rabbits following *Crotalus* envenomation. *Proc West Pharmacol Soc*. 1970;13:99-105.
19. Smith TW, Lloyd BL, Spicer N, et al. Immunogenicity and kinetics of distribution and elimination of sheep digoxin-specific IgG and Fab fragments in the rabbit and baboon. *Clin Exp Immunol*. 1979;36:384-396.
20. Gillissen A, Theakston RD, Barth J, May B, Krieg M, Warrell DA. Neurotoxicity, haemostatic disturbances and haemolytic anaemia after a bite by a Tunisian saw-scaled or carpet viper (*Echis 'pyramidalis'*-complex): failure of antivenom treatment. *Toxicol*. 1994;32:937-944.
21. Meyer WP, Habib AG, Onayade AA, et al. First clinical experiences with a new ovine Fab *Echis ocellatus* snake bite antivenom in Nigeria: randomized comparative trial with Institute Pasteur serum (IPSER) Africa antivenom. *Am J Trop Med Hyg*. 1997;56:291-300.
22. Ho M, Warrell MJ, Warrell DA, Bidwell D, Voler A. A critical reappraisal of the use of enzyme-linked immunosorbent assays in the study of snakebite. *Toxicol*. 1986;24:211-221.
23. Ownby CL, Reisbeck SL, Allen R. Levels of therapeutic antivenin and venom in a human snakebite victim. *South Med J*. 1996;89:803-806.
24. Theakston RDG, Phillips RE, Warrell DA, et al. Envenoming by the common krait (*Bungarus caeruleus*) and Sri Lankan cobra (*Naja naja naja*): efficacy and complications of therapy with Haffkine antivenom. *Trans Royal Soc Trop Med Hyg*. 1990;34:301-308.
25. Sorensen HNH, Faber V, Svehag SE. Circulating immune complexes, complement activation kinetics and serum sickness following treatment with heterologous anti-snake venom globulin. *Scand J Immunol*. 1978;7:25-33.
26. Seifert SA, Boyer LV, Dart RC, et al. Relationship of venom effects to venom antigen and antivenom serum concentrations in a patient with *Crotalus atrox* envenomation treated with a Fab antivenom. *Ann Emerg Med*. 1997;30:49-53.
27. Wenger TL. Experience with digoxin immune Fab (ovine) in patients with renal impairment. *Am J Emerg Med*. 1991;9(2 suppl 1):21-23.
28. Smith DC, Reddi KR, Laing G, Theakston RGD, Landon J. An affinity purified ovine antivenom for the treatment of *Vipera berus* envenoming. *Toxicol*. 1992;30:865-871.
29. Bernard DB, Salant DJ. Clinical approach to the patient with proteinuria and the nephrotic syndrome. In: Jacobson HR, Striker GE, Klahr S, eds. *The Principles and Practice of Nephrology*. Philadelphia, Pa: BC Decker Inc; 1991:250-252.
30. Iwanaga S, Suzuki T. Enzymes in snake venom. In: Lee C-Y, ed. *Snake Venoms*. New York, NY: Springer-Verlag; 1979:65.
31. Bajwa SS, Markland FS, Russell FE. Fibrinolytic enzymes in Western diamondback rattlesnake (*Crotalus atrox*) venom. *Toxicol*. 1980;18:285-190.